# Patients' Guide to Phalloplasty Techniques

## St Peter's Andrology Centre, London

St Peter's Andrology Centre is an independent unit in London offering genital reconstructive surgery to transmale patients, primarily to those funded by the NHS. We operate at the Hospital of St John and St Elizabeth, Highgate Private Hospital and the Spire Thames Valley Hospital. In addition to these three hospitals we see outpatients in our private consulting rooms in Harley Street.

This document outlines the various procedures performed at our unit.

## PATIENT'S RESPONSIBILITIES

Please bring dressing gowns, shoes, toiletries and appropriate i.e. loose clothing to go home in postoperatively. Track suit bottoms are ideal.

Please also bring with you any medication that you take regularly together with its packaging.

It is your responsibility to arrange transport home so please make arrangements beforehand or bring sufficient funds to do so from hospital. We will normally let you know how many nights you would need to stay in hospital to make planning easier but this does vary from person to person and on the speed of your recovery so please do allow for a certain amount of flexibility in your travel plans. A pillow or soft cushion to sit on is very useful.

You do need to ensure that you have appropriate accommodation to go home to following the surgery and that if you are planning to have friends or family to be with you once you go home that this has all been arranged before you come into hospital.

Please make contact with your GP practice in advance of your operation to let them know that it is coming up. If possible bring with you the telephone number that our ward staff should ring to talk to the practice nurse or district nurse who will be looking after you once you go home. Depending on the procedure that you are having, the ward staff may need to talk to them before you go home and in any case will want to fax through details of your surgery and postoperative care.

Finally, be aware that whilst there will be no charge to you for any aspect of your treatment in the hospital if you are funded by the NHS, certain non-medical services would be charged to you should you use them. Examples are telephone calls, newspapers and visitors' meals but if in doubt please check with a member of staff.

## PREOPERATIVE PREPARATION

Regardless of the procedure that is being performed, the better your general health before surgery the easier you will find it. Due to the increased risk of complications and poor outcomes we will not list you for surgery involving skin grafts or flaps until you have stopped smoking for at least two months and it will normally be about six months from stopping smoking till the date of the surgery as the surgical risk goes down with time. It is important that you then continue to refrain from smoking for at least six weeks after the surgery. If you use nicotine replacement of any sort then this should be discontinued a month before surgery and not started again until a month afterwards.

We do not perform non-emergency surgery if your Body Mass Index (BMI) is over 30 (use the male tables) as this too causes significant risks of complications. Equally the hospitals require patients to have a BMI of at least 18 for elective surgery to proceed. Be aware though that these are the extreme limits and generally speaking you can expect better results by being well within them rather than on the borderline.

| **Height** | **Weight (kg)** | |
|---|---|---|
| | **BMI = 18** | **BMI = 30** |
| 4'10" | 40 | 66 |
| 5' | 42 | 70 |
| 5'2" | 45 | 75 |
| 5'4" | 48 | 80 |
| 5'6" | 51 | 85 |
| 5'8" | 54 | 90 |
| 5'10" | 57 | 95 |
| 6' | 61 | 100 |

## HYSTERECTOMY AND MASTECTOMY

Many patients have already had hysterectomy and mastectomy (chest surgery) performed before being referred to us for phalloplasty surgery.

Mastectomy is normally the first operation undergone by patients but there is no absolute reason why it cannot be undertaken at any stage in the process. We do not provide this service however.

In patients undergoing pubic phalloplasty (see below) we commonly perform open hysterectomy during the course of the procedure. If an open operation is necessary prior to phalloplasty, we prefer this to be done through a midline skin incision so that the possibility of a pubic phalloplasty is not compromised later. If a radial artery phalloplasty has already been decided on then a Pfannenstiel incision (transverse suprapubic) is perfectly acceptable although a laparoscopic ("keyhole") procedure is preferable. Laparoscopic surgery leaves fewer scars and has a faster recovery which is important as patients will be having multiple operations later.

In patients undergoing free flap phalloplasty (radial artery forearm or anterolateral thigh methods) we can perform laparoscopically assisted vaginal hysterectomy at the time of join-up urethroplasty (see below). This may also be appropriate in patients undergoing pubic phalloplasty or metoidioplasty.

Once you have had the ovaries removed, your testosterone requirement may decrease. Please see your GP or Gender Clinic Specialist to assess and discuss testosterone reduction as necessary about two months later.

# PHALLOPLASTY

The majority of our group of patients choose to have a normal adult sized phalloplasty. We use two main methods to create the phallus: radial artery phalloplasty and pubic phalloplasty. A small percentage of patients may also be suitable for an anterolateral thigh flap phalloplasty. There is a smaller subgroup of patients who prefer to convert the enlarged clitoris into a mini-phallus or metoidioplasty.

Our techniques have evolved over time and this document concentrates on the procedures currently offered as part of a primary pathway. As older techniques become superceded they remain within our armoury to solve particular problems that may arise but they are not described here in the interests of clarity.

Despite advances in surgical techniques there is no perfect technique and each approach has its own drawbacks. Patients will need to consider the following factors when deciding which approach is most appropriate to their needs:

- standing to void
- locker room appearance
- penetrative sex
- scarring potential
- sexual sensation
- removal of external and internal female parts
- number of operations
- potential complications
- donor site problems

## Operative Staging

We split the surgery into manageable stages so that the operations are not too complicated and patients' bodies can get a rest in between each stage, which is important.

- STAGE 1: Formation of the phallus and/or neo-urethra in phallus
- STAGE 2: Glans sculpting, scrotoplasty and connect neo-urethra to bladder
- STAGE 3: Erectile and testicular prosthesis

If a patient wants a neo-urethra (urinary passage through the phallus) then this has to be completed before the penile prosthesis is implanted. If there is an unsatisfactory result or complication from any stage then this is normally corrected before moving on to the next stage.

It is important to realise that there may sometimes be more than one operation involved at each stage and there should normally be at least three months in between each operation. Patients having all three stages can therefore take 12-18 months to complete their surgery even if there are no complications requiring extra admissions. It is not uncommon for the entire process to require two to three years (or even longer if there are problems fitting in the surgery around the requirements of employment, holidays etc.).

Patients should also be aware that we will not list people for surgery until they are ready to proceed. This means for example that we will not list someone for surgery in the expectation that they will have reached their target weight by the time of surgery. Similarly we do not list people for the next stage of surgery until they have completely recovered from the previous stage. This is partly because of difficulties predicting how quickly a wound will heal and also because the final outcome of one stage may affect the details of the surgery required at the next procedure.

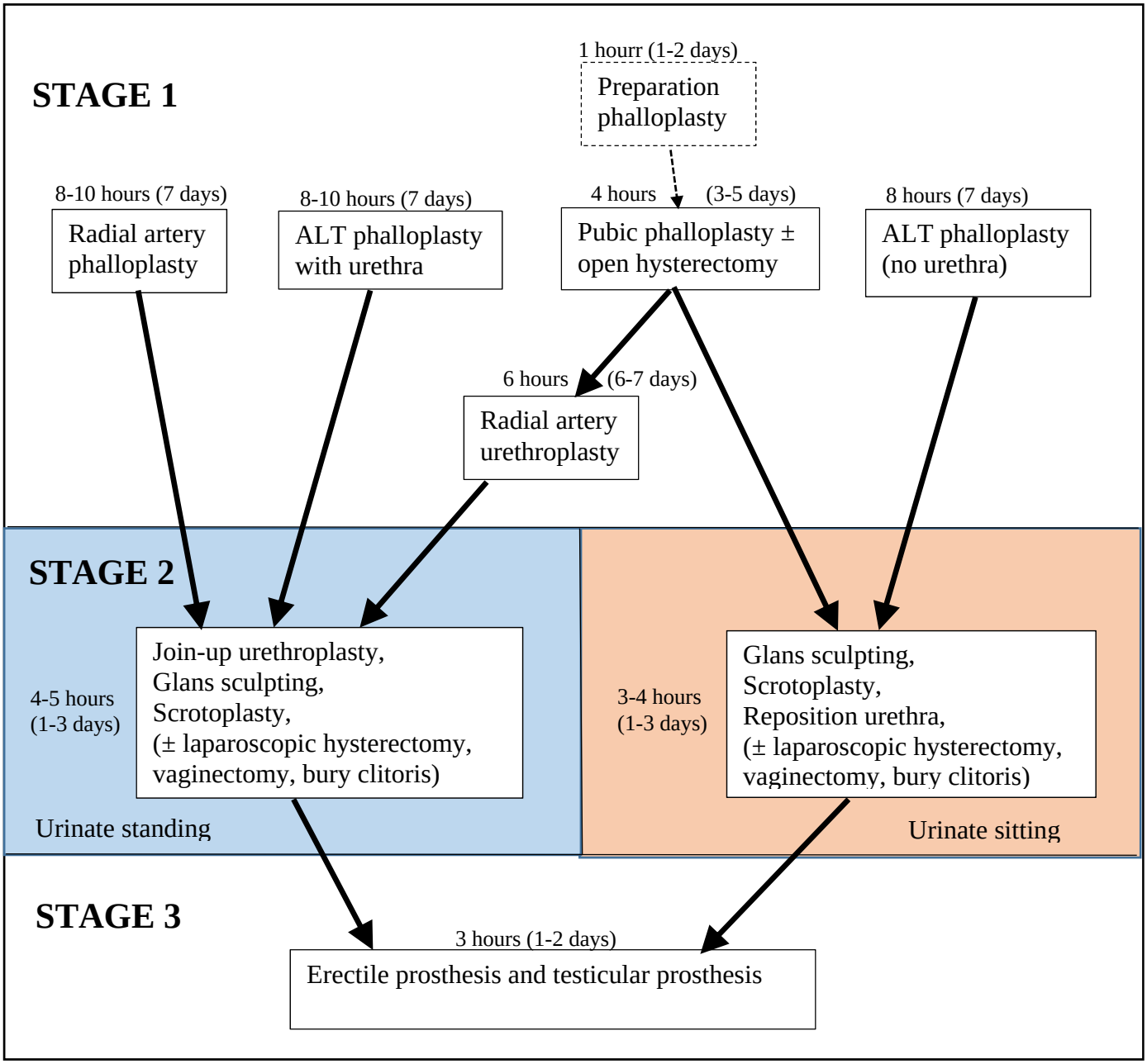


**Figure 1. Standard surgical pathways with approximate operative times in hours and hospital stay in days for voiding standing or sitting and with or without prostheses.**

# Formation of Phallus

## Radial Artery Phalloplasty (Forearm free flap phalloplasty)

We have been performing this surgery since 1996 using the original technique as described by Chang in 1984. The forearm flap has the thinnest skin, reasonable fat content and is not usually hairy on the urethral segment. In addition it has the most reliable anatomy when compared to all the other free flap techniques and is fairly easy to harvest. This is the procedure of choice if standing and voiding from the tip, cosmesis and sensation are the prime requirements.

The main disadvantage for patients is the cosmetic appearance of the skin graft on the forearm where tissue has been taken to construct the phallus.

**Figure 2. Varying donor site defects on arms following radial artery phalloplasty. From left to right: severe defect one year after surgery, full thickness skin graft, split skin graft.**

It is important to appreciate that actual problems with the function of the hand and arm are extremely uncommon and always have been in our series of patients. We are aware however that the appearance of the arm after surgery is extremely important to our patients and much effort has gone into improving this aspect. Modern dressing techniques using silicone, absorbable monofilament sutures and fewer dressing changes combined with careful attention to graft placement has resulted in significant improvements in the cosmetic appearance of the arm following surgery.

**Figure 3. More recent radial artery phalloplasty donor site pictures**

### *Operative technique*

A flap from the urethral segment of the forearm skin is formed into a skin-lined tube that will eventually be the neo-urethra (Figure 4). This tube is then rolled up like a Swiss Roll within a larger flap which has the skin on the outside. This tube within a tube is then transplanted to the pubic area and microsurgical anastomoses made to connect the artery, veins and nerves. The radial artery from the arm is transplanted to provide a blood supply to the phallus via the inferior epigastric artery from the lower abdominal muscles. The lower neo-urethral opening is placed to the side of the clitoris ready to be connected to the native urethral opening in the future.

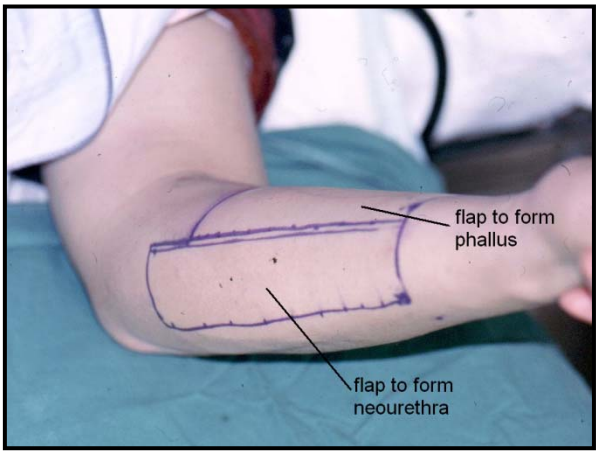


**Figure 4. Forearm marked out for radial artery phalloplasty with site of flaps**

### *Donor site defect*

We use lower buttock skin crease full thickness grafts for the forearm grafts instead of using groin skin, axillary skin or abdominal skin. The scar from buttock skin is easily hidden and the hair quality is fairly fine and appropriate for most forearms.

**Figure 5. Scars following harvesting of skin from buttocks**

If a patient has no spare skin anywhere then we take split thickness skin graft from the thigh to cover the forearm. Split thickness skin graft is hairless, very sensitive to sunlight damage and also contracts more which may impair arm function. However we have not had many seriously significant problems with our patients in the long term. Full thickness skin does grow hair, is thicker, stretches more and looks and feels better. In addition it takes tattoo ink better if patients want to tattoo the graft. We suggest waiting a year for the scar to stabilise before starting a tattoo. We recommend that patients avoid sunlight exposure to the skin grafts for about two years. It is also important to use skin moisturisers as often as possible to hydrate the grafted skin and maintain pliability.

The standard forearm skin length measurement of the phallus is 14 cm but if the forearm is of small size then we make a smaller phallus (12-13 cm) to aid skin closure, increase usable radial artery

length and reduce forearm morbidity. This gives a very acceptable cosmetic result. The length and girth of the phallus once made depends on the weight of the fat and skin elasticity so patients end up with range of sizes (some bigger, some smaller). We aim for a girth of about 13 cm which leaves enough space for the erectile device. We connect normal sensory as well as erogenous nerves to the phallus and about 90% of our patients to date have at least some touch/sexual sensation in the phallus. The forearm flap usually has 3 nerves that come with it and is therefore more likely to develop sensation than any other kind of phalloplasty. Nerves do grow slowly and it can take a couple of years for sensation to appear.

**Figure 6. Radial artery phalloplasty**

## Pubic Phalloplasty

This is the operation of choice if no urethra is required but phallus size and penetrative sex is important with minimal visible donor site scarring. A patient having this option will then need to sit to void urine. If a urethra is required, then a good quality neo-urethra can be incorporated into a pubic phalloplasty later by performing a radial artery urethroplasty procedure. We don't advocate using a skin graft or labial flap type urethroplasty as the results are poorer in the long term and the blood supply of the urethra is more delicate and easily damaged particularly if an erectile device is inserted later.

### *Operative technique*

A rectangular shaped skin flap (14 cm long by 12 cm wide) is raised from the lower abdominal skin but still in continuity with the clitoral and pubic area. If there has been a transverse hysterectomy scar then we mark out the proposed flap, raise it and then put it back on the abdomen and wait for at least six weeks. This is to make sure that there is sufficient blood supply for a phallus to survive. The rectangular skin flap is folded in a tubular fashion to form the phallus.

Abdominal skin is mobilised and brought down to cover the defect. We use lateral hip skin flaps rotated in to help close the skin defect, which reduces the risk of the phallus being tethered upwards. The scar does go right across the abdomen but usually can be hidden by underpants. The main complaint from patients is that they lose their pubic hair using this technique.

If there is difficulty closing the skin defect then we initially allow the phallus to ride high (ie: pointing upwards) and then use groin crease skin flaps to drop the phallus down at a later stage, giving more pubic hair. This problem is more likely to arise in patients with little abdominal fat.

These phalluses can also be rather large particularly in girth and we have had to deliberately reduce the girth and even length in some patients to allow comfortable sexual intercourse with their partner. They have less sensation than the radial artery phalloplasties when compared with the radial artery

phalloplasties. They have no distal phallus sensation (feeling towards the tip) because all the nerves get cut during the flap elevation.

**Figure 7. Postoperative pubic phalloplasty**

## Anterolateral thigh flap phalloplasty (ALT)

This type of phalloplasty is made from the skin and fat on the front and side of the thigh. Very few patients are suitable for this method as it requires that the subcutaneous fat on the thigh be not too thick. In addition if a neo-urethra is required then the urethral segment must not be hairy. In general terms, the skin itself is also much thicker/coarser than that of the forearm.

For ALT phalloplasty with urethra the flap design and construction is the same as for the forearm technique: a tube within a tube. The flap skin length dimension is usually 14-16 cm as there is more available skin on the thigh compared to the forearm. Usually the feeding artery and veins are very long and arise from near the hip joint and it is therefore possible to tunnel the whole flap under the quadriceps muscle to the groin without disconnecting and reconnecting the blood vessels (pedicled flap). There is however only a single nerve with this flap so even with a nerve hook-up, sensation is not as good as with the forearm flap method.

The large donor site defect is covered with a split skin graft from the other thigh and is not particularly cosmetic but can be covered with a long pair of shorts quite easily. We do not offer this type of phalloplasty if the patient has significant knee problems as these may get worse post-operatively. In any case the thigh muscles tend to bulge quite a bit afterwards but the split skin graft shrinks considerably as it matures and tends to hold the muscles back in place. The quadriceps muscles are deliberately cut to release the feeding artery and vein but are sutured back together at the end of the procedure. Healing takes place in much the same was as a bad sports muscle tear/injury would do. Patients are able to mobilise within a couple of days.

For ALT phalloplasty without urethra, a smaller width flap is taken and the hairiness does not matter as that can be dealt with later. This option is sometimes chosen if a patient wants a potentially sensate phallus but has little abdominal fat, cannot use the forearm and is happy to void sitting down.

**Figure 8. Anterolateral thigh flap phalloplasty. Donor site for the phalloplasty was this patient's left thigh: the scar on his right leg is from the skin graft covering the donor site defect**

## Metoidioplasty (Mini-phallus)

This operation is selected by those who need to void standing but are not interested in phallus size or having penetrative sexual intercourse. Sometimes they just want the appearance of a small penis and scrotum and are happy to void sitting. It is not a common choice in our group of patients and in our experience about 25% of patients having this operation later regret not having had a larger phallus constructed which allows them to have sexual intercourse.

### *Operative technique*

The procedure involves bringing the urethral opening up to the tip of the clitoris rather than the side and the clitoris is formed into a pseudo-glans. The remaining non-hairy inner labial folds are excised and the hairy outer labial skin is dropped down to make the mini-phallus stick out more. The neo-urethra is usually constructed in two stages with a buccal graft taken from the lining of the mouth grafted on first to form the lining of the new segment of urethra. This is allowed to heal before the surgery is completed at a second stage about six months later. Laparoscopic hysterectomy and vaginectomy can be performed at the same time as the second stage.

If the patient does not need to void standing then the mini-phallus and scrotum are formed in one operation with laparoscopic hysterectomy and/or vaginectomy as required. The native urethral opening is then repositioned discretely just under the scrotum so no female-looking parts are retained.

Small testicular prostheses are inserted later if required.

Best results are obtained when there is significant clitoral enlargement from long-term testosterone treatment. If the clitoris is small or the patient is overweight then this is not a recommended procedure. One of the problems is that the urethral width is quite narrow for technical reasons and voiding difficulties and strictures are not uncommon.

**Figure 9. Metoidioplasty**

### Hair Removal

If there is hair on the segment of skin that is used to form the neo-urethra then this can cause problems later and will need to be significantly reduced prior to surgery. If that is so we will advise you of this and the surgeon will mark out the area that needs hair removal. Funding for this is normally available for NHS patients and we can discuss that with you. Depending on your hair type you may need to undergo electrolysis or be suitable for laser hair removal which is generally quicker. It is therefore a good idea to use a clinic that offers all forms of treatment.

Once the hair removal has been completed we wait three months before listing you for surgery to ensure that the area remains suitable for surgery with no significant regrowth of hair. Even if the hair removal is for cosmetic reasons we still will not operate within six weeks of the most recent session. This is to avoid the possibility of the treatment interfering with the surgical outcome.

Hair removal for cosmetic reasons (i.e.: because you do not like the appearance of hair on the penis) is not normally funded by the NHS but can be undertaken either before surgery (when the areas concerned are relatively flat) or afterwards (when it can be seen exactly which hairs require removal).

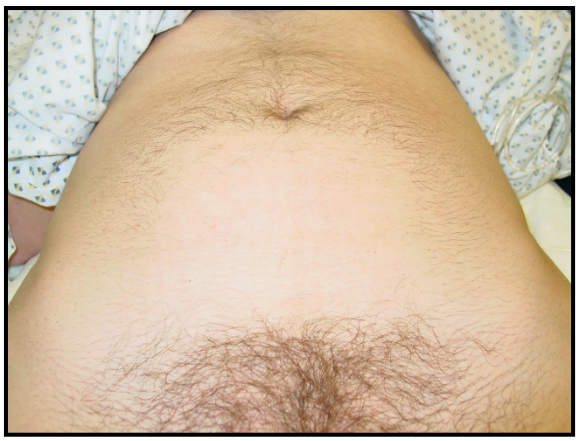

**Figure 10. Donor site for pubic phalloplasty following preoperative laser hair removal**

## Formation of Neo-urethra

This used to be a major problem for pubic phalloplasty patients but since the advent of the radial artery urethroplasty (RAU) technique, we can now get just as good quality type of neo-urethra as for a radial artery phalloplasty and patients can now easily void from the tip of a pubic phalloplasty if required. Prior to the RAU technique, we used a multi-stage urethroplasty technique using labial

flaps and skin grafts but most patients ended up with a urethral meatus (urinary opening) about a third to half way up the underside of the phallus due to complications.

## Radial Artery Urethroplasty

A better technique of incorporating a urethra into a phalloplasty is to use a variant of the radial artery phalloplasty using a much smaller flap as it is just used to form the urethral section rather than the full phallus.

This is a more complex procedure with a correspondingly longer stay in hospital and recovery times than the labial urethroplasty but it does have much better outcomes. It allows us to bring the neo-urethra to the tip of the phallus without the complications associated with the labial urethroplasty. It does however result in scarring on the arm but this is a much smaller scar than for a full radial artery phalloplasty. A useful side effect of the surgery is that because there is a nerve supply to the neo-urethra in 50% of cases, there may be some sensation to the tip of the phallus after this surgery.

**Figure 11. Radial artery urethroplasty**

## Join-Up Urethroplasty

Whether the neo-urethra has been formed following a pubic phalloplasty or at the time of radial artery phalloplasty a join-up urethroplasty is needed before urine can flow through the new opening. This involves taking a strip of vaginal skin and the other non-hairy inner labial skin and using them to connect the native urethra (existing urine tube) to the previous opening next to the clitoris.

## Catheters

Catheters are used for two main purposes. Firstly, they allow the patient to pass urine while the new urethra is healing. They also have an important role in keeping the size and shape of the neo-urethral lumen (passageway) in much the same way as a sleeper does after a piercing.

If they are removed too early then the lumen can narrow. However, being foreign bodies, catheters become completely colonised with bacteria within two weeks and can also cause mechanical irritation and therefore damage to the neo-urethra. A good compromise seems to be to leave the catheter in for between seven and ten days in phallic neo-urethras that have not yet been connected to the bladder. A shorter period is more desirable if possible.

In the join-up urethroplasty (or metoidioplasty) two catheters are used. One is put through the abdomen into the bladder (suprapubic) and one through the neo-urethra to keep the lumen open. The luminal one is removed at seven days but the patient must void only through the suprapubic catheter until about day 21. This is to stop the urine dissolving the absorbable sutures that are used to make the urethral hook-up too early. At this point the patient performs a trial void through the neo-urethra and if all is well then the suprapubic catheter is removed.

## Fistulae and Strictures

If there is a urine leak or fistula it is commonly just inside the vaginal opening where the neo-urethra joins the native urethra. About 50% of minor leaks (a few drops) will heal spontaneously as long as the distal urethra (downstream segment) is not narrowed. We leave patients for a minimum of three months to allow this to happen and also to allow the tissues to thicken up so that a repair is more likely to succeed. There is no point attempting to repair it earlier as it will invariably make the hole even bigger. Rather than undergoing further surgery, some patients manage small fistulae by blocking them with a clean fingertip during voiding (ie: as if playing the flute) which is perfectly acceptable. If there is a lot of hairy skin inside the neo-urethra then small hair follicle infections can form abscesses which rupture to the outside forming new fistulae. This is why we try to use as little hairy skin as possible.

Similar principles apply if there is a stricture. The stricture needs to mature so that it does not narrow further after the repair has been performed. This may require a suprapubic catheter being inserted to divert the urine for a few weeks first. Some patients manage with regular self-dilation and generally as long as a size 14F catheter can get past the stricture, it is good enough to pass urine through. If a repair is necessary then we use local skin flaps, if available, otherwise buccal mucosa or posterior auricular skin.

Redo fistula repairs have an increasingly poorer success rate so if a 3rd repair is needed, it is done in conjunction with a vaginectomy which has an almost 0% fistula rate.

## Vagina

We do not offer a total vaginectomy service as this is risky surgery with significant bleeding problems. Because a piece of the front wall of the vagina is used both in metoidioplasty as well as join-up urethroplasty the vaginal opening in all patients with a neo-urethra will be much narrowed. For the small number of patients who intend to continue using their vaginas we would suggest that they do not have the urethra formed. For those who wish to use the vagina after a neo-urethra has been formed, they will need to carefully dilate the vagina once the neo-urethra has healed but this is not always successful. For patients who need to continue having cervical smears but have very narrow vaginal openings, we can sometimes widen this sufficiently to allow smears to be taken comfortably but not really enough for intercourse.

For patients who require vaginectomy we offer ablation vaginectomy whereby the skin lining the inside the vagina is removed by electro-vaporization using heat treatment (high energy 'pure cut setting' electrocautery). The vaginal skin is the source of the bulk of unwanted genital secretions. This is much less risky than a total vaginectomy and has fewer complications than the mucosal excision vaginectomy technique we used to prefer. Once the vaginal opening is closed to give a male perineum appearance, the raw muscular sides of the vagina stick to each other and obliterate the vaginal space over a few months. If required this procedure is normally performed at the time of the join-up urethroplasty though it can be performed at any stage other than with the implantation of a penile prosthesis. Occasionally a small piece of the vaginal skin is retained inside and may present as a new cyst in the perineum a year or two later. This is easily treated by re-vaporization.

Other sources of genital secretion are the peri-urethral glands, which are normally incorporated into the neo-urethra during the join-up urethroplasty, and Bartholin's glands at the old vaginal entrance. The latter can also be a cause of a perineal cyst after ablation vaginectomy and is easily treated by excision.

### Clitoris

Sexual sensation is extremely important to most patients. The best way to preserve sensation in the clitoris is to leave it where it is. However it does sit between the two testicular prostheses and is impossible to conceal.

With the radial artery phalloplasty or ALT phalloplasty patients, it is now routine practice to disconnect one of the two large nerves from the clitoris and attach it to the nerves that come with the phallus for erogenous sensation. Most patients perceive clitoral sensation as unchanged even with just one nerve left.

Most patients want a completely male perineal appearance and request that the clitoris be buried under the skin. We mobilise it by releasing the pink skin underneath and burying it much higher up just under the skin near the base of the phalloplasty. The top layer of skin has to first be removed from the clitoris as otherwise patients will have recurrent abscess formation at the site. It typically takes about a month or so for the hidden clitoris to stabilise and the nerve endings to re-connect. Typical patients' comments are '50% harder to find it to stimulate but orgasms normally'. It is important not to put on a lot of weight after as the clitoris may disconnect from the skin and become very inaccessible.

## Scrotoplasty

If there is insufficient labia majora skin to insert a testicular prosthesis into directly or if the patient's thighs are large then a formal scrotoplasty is needed to bring the neo-scrotum in front of the thighs.

The best cosmetic appearance is obtained by forming the scrotum at the time of vaginectomy and join-up urethroplasty with burying of the clitoris. If the clitoris is not buried or a vaginectomy not performed then the scrotum is inevitably bifid, appearing somewhat split in two. A single scrotal sac is made which we then ask patients to stretch as much as possible before the Stage 3 operation.

## Glans Sculpting, Testicular Prostheses Etc

Regardless of which sort of phalloplasty has been undertaken, once the urinary tract has been completed patients move on to implantation of prostheses if required. Before the penile prosthesis itself is implanted we undertake glans sculpting and carry out any final shaping that is necessary, excising skin tags or "dog-ears" and tidying up scars as necessary. The reservoir of the penile prosthesis may be implanted at this stage together with a testicular prosthesis on occasion. Currently these procedures are normally performed at the same time as the join-up urethroplasty though in the past this was a separate stage of surgery.

**Figure 12. Pubic phalloplasty following glans sculpting and implantation of testicular prostheses**

## Glans Sculpting

We use a modified Norfolk technique using a full-thickness skin graft rather than split skin grafts. A circumferential skin flap (Fig 13a) is raised like the brim of a hat which is then rolled in (Fig 13b). The use of a full thickness skin flap allows a nice helmet or mushroom head to be created (Fig 13c). Skin graft is then wrapped fairly tightly around the bare fat below the head to cause a slight constriction as it heals to accentuate the bulbousness of the head. The appearance is that of a circumcised penis. As with all skin grafts the results are unpredictable but most patients have an acceptable cosmetic result. We used to use split-thickness skin grafts as in other units but have found that the cosmetic appearance in our hands is better with full thickness skin. Also we believe the results are better when the glans sculpting is done separately from the Stage 1 phalloplasty surgery as we don't need to worry about disturbing the blood supply of the newly formed phallus then.

**Figure 13. Glans sculpting**

## Testicular Prostheses

Patients with erectile devices normally have a single large/medium testis prosthesis on one side and an erectile pump on the other as there is no space for two testes and a pump. The size we put in depends on the looseness of the hairy outer labial skin and we try to use a large prosthesis if possible.

If a join-up urethroplasty has been previously performed then there may be less available skin on the side that has been operated on. Another consideration is the amount of space between the thighs. Often two perfectly positioned testes will migrate once the patient returns to normal activity resulting in one testis going lower and the other upwards to the phallus. If space is at a premium then a medium prosthesis is

inserted to keep the two about level. In terms of appearance the medium and large look about the same size postoperatively!

We use solid silicone gel prostheses which are pretty much rupture-proof and should last a lifetime. Their shape is oval rather than round in keeping with a real testicle.

### Excise Excess Skin

We will excise any untidy bits of skin usually at the end of wound lines and frequently use these bits of skin as skin graft for the glans sculpting rather than excising a new piece of skin. Many patients want to have the natural curve at the side of their hips flattened. This is not due to our surgery but due to their natural shape and requests for this to be done by us are declined as it is not part of our phalloplasty service.

## Penile Prosthesis

The history of phalloplasty has two holy grails: the first being to pass urine from the tip of the phallus and the second to be able to have penetrative sex. The potential problems with the construction of the urethra have already been discussed earlier. To understand the theory behind penile prosthesis for phalloplasty it is first necessary to understand how the natural penis in cis-males functions.

### Normal Male Anatomy

The penis consists of three tubes. The two larger tubes lie side by side on the top and contain the erectile tissue. The smaller tube contains the urethra and also forms the whole glans or head of the penis and lies underneath. The erectile tissue tubes, called corpora cavernosum, are made of a tough but partially elastic fibrous tissue (tunica) that is anchored to the lower end of the pubic bone. Anchorage provides stability of the erect penis and prevents the penis falling back with penetrative sex. The elasticity of the tunica allows some expansion of the width and length of the erect penis. The tough fibrous nature of the tunica allows the pressure inside the erect penis to rise well above the normal blood pressure and makes it hard and rigid. The erectile tissue inside the corpora is like a sponge in that it can expand greatly in size with blood when erect allowing a significant difference in appearance between the flaccid and erect penis. All these factors need to be artificially reproduced in the phallus.

### Rigidity and Stability

Incorporating pieces of bone or cartilage inside the phallus to make it rigid has been tried. The problem is anchoring it to the pubis as although this could be done one would not then be able to move the phallus around and it would be permanently stiff and in the same position. In any case, cartilage gradually softens so it is ineffective in the long term.

We use permanent stitches to attach the penile prosthesis to the lower edge of the pubic bone. Rather than putting sutures through the prosthesis, we use a Dacron™ (polyester fabric) sock or sheath to recreate the tunica of the corpora cavernosum. This is then attached to the bone with the bone sutures. Dacron is synthetic material used in vascular surgery to replace or repair major blood vessels such as the aorta and is very tough. Over time, it becomes very fibrotic and effectively functions like the real tunica and protects the prosthesis buried inside. If the prosthesis needs replacing, we just open the Dacron sheath and change the prosthesis over without having to reconnect things to the bone again. Our preference is to use a Dacron sock at the base and a Dacron cap at the tip to allow the single cylinder to expand more in the middle and prevent curvature. If the phallus is very wide then we

use a complete Dacron sheath to bulk up the cylinder or use 2 cylinders. This covers the anchorage and protective functions of the tunica.

## Penile prostheses

There are two main classes of penile prosthesis, the malleable and inflatable models. The malleable or semi-rigid prostheses consist of a silicone rod with a flexible steel core which allows it to be both stiff and bendable. A newer type has interlocking metal segments with a cable connector instead of a steel core allowing flexibility and when the cable is manipulated, the whole thing locks and becomes rigid. There are no external moving parts and they are to all purposes indestructible. They have been used in phalloplasty, as they are simple to insert. Unfortunately, the drawback is their rigidity, which exerts constant pressure on the skin in spite of the Dacron sheath, and erosions are common. Also having a permanently stiff phallus is very inconvenient.

Because of the above problems with the semi-rigid prostheses we mainly offer inflatable prostheses. This is essentially a balloon that can be filled with fluid to create rigidity when an erection is needed. This is much more like the normal erectile spongy tissue. We cannot however reproduce the elastic function of the tunica because the phallus skin is fixed in size.

Inflatable prostheses come in three basic models from various companies. They all consist of three components which are the cylinders, pump and reservoir. The pump regulates the flow of fluid between the reservoir and cylinders, thereby controlling the erections. The cylinders give the rigidity for penetration and the reservoir stores the fluid when no erection is required. The fluid used is usually saline but x-ray contrast is sometimes used. A one-part inflatable has all three components combined in one cylinder. The pump is at the glans end whilst the reservoir is at the bone end with the cylinder in the middle. A two-part inflatable has the reservoir and cylinder combined in the cylinders with a separate pump. The reservoir is at the bone end with the rest of the cylinder being the inflatable component. A three-part inflatable has the cylinders, pump and reservoir as three separate components.

**Figure 14. Three piece inflatable penile prosthesis (Coloplast Titan Touch)**

There are a number of advantages of the inflatable over the semi-rigid. Firstly, it functions more naturally. Secondly, in the flaccid state there is much less pressure on the skin and so less likelihood of erosion. The cylinders can expand in girth and with a high pressure of fluid inside can be just as hard as a semi-rigid device. Disadvantages include a higher infection rate because it has more components and also a mechanical breakdown risk as there are moving parts. Our data suggest that about 30% of inflatable prosthesis will fail for mechanical reasons in the first 10 years and require replacement.

## Current technique

We use a three-part inflatable for all patients unless there are special reasons to use a two-part inflatable. We found that the two-part inflatable prostheses were less flexible and therefore not as good as the three-part prosthesis.

The body will form a non-elastic fibrous capsule around all foreign material including the cylinders of the penile prosthesis. Unless patients start pumping up the cylinders very early on, they may find that the erection is not stiff enough as the cylinders cannot expand. We get patients to start cycling the prosthesis on a daily basis at two weeks, sometimes earlier depending on pain control. We do not have to worry about the reservoir nowadays as they come with special valves and we often let patients go home with the cylinders partly inflated to maintain the shape. The phallus has to be kept pressed up against the abdomen during this time. If it is bent downwards then it may be possible to loosen the bone anchor sutures at the base, which will make penetration difficult and more painful as there will then be no stability.

Normally only one cylinder is used because together with the Dacron it is quite bulky and gives sufficient rigidity. If there is a urethra then there is very rarely sufficient space for two cylinders. Some of the larger pubic phalluses need two cylinders because of their girth. It is important to leave some fat between the cylinder and the skin to prevent erosion in the future. Patients are advised not to attempt intercourse for at least six weeks to give time for the fibrous capsules to form and more importantly to allow the bone anchoring sutures to become rock solid and provide support for the implants. We also advise all patients to use condoms to help prevent infection getting in through tiny abrasions in the phallic skin and to help with lubrication. Condoms also firm up the fat surrounding the cylinder, thus improving rigidity.

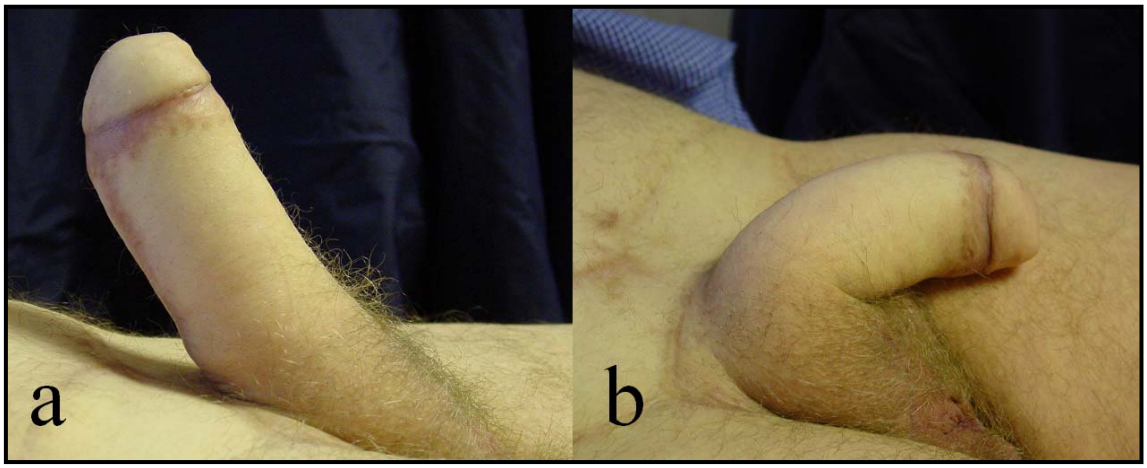


**Figure 15. Pubic phalloplasty with inflatable penile prosthesis: (a) inflated and (b) deflated**

## Complications

The two enemies of penile implants are infection and erosion. The latter problem is minimised by all the above techniques. Infection is by far the biggest problem. It is usually introduced at the time of initial surgery from bacteria on the patient's skin. If there is infection we are fighting a losing battle and the end result is that the whole implant has to come out and we start again. We utilise strict aseptic technique and use perioperative antibiotics for the patients. In addition, patients have an antiseptic bath preoperatively and have nasal antibiotic cream to kill the bacteria in their nose. The space in the phallus is washed with antiseptic solution as well as antibiotics as is the Dacron sheath. We try to avoid the implant touching the skin during surgery which also helps. We use antibiotic

impregnated prostheses and in a large series reported from America there has been a significant reduction in infection problems even with patients who have had multiple implant revisions and other high-risk groups.

A sensate phallus is less likely to have erosion problems as innervated skin is tougher and provides early warning signals in the form of pain if the prosthesis is getting too close to the skin.

## CONCLUSION

In the absence of the ideal technique each patient needs to make an informed choice of the procedure which best meets their individual requirements. This inevitably requires a degree of compromise. The radial artery phalloplasty gives the best results in terms of urinary function but is an extremely traumatic procedure with long-term damage to the donor arm. The scars from the pubic phalloplasty are far less conspicuous and the procedure itself involves shorter stays in hospital though generally more of them and spread out over a longer period of time. Standing to urinate should be possible with the pubic phalloplasty by using the RAU technique. If standing to urinate is the only consideration then a metoidioplasty may be the preferred option but our experience is that 25% of patients return later requiring a cosmetically acceptable phallus and/or sexual function. Sensation is often possible with the radial artery phalloplasty but should not be expected in the pubic phalloplasty. Whether a patient opts for the pubic phalloplasty or the radial artery phalloplasty he can expect to end up with a cosmetically acceptable phallus suitable for penetrative sexual intercourse.

## RELEVANT PUBLICATIONS FROM ST PETER'S ANDROLOGY CENTRE

1. Pedicled pubic phalloplasty in females with gender dysphoria. Bettocchi C, Ralph DJ, Pryor JP. BJU Int. 2005 Jan;95(1):120-4.
2. Total phallic reconstruction after penile amputation for carcinoma. Garaffa G, Raheem AA, Christopher NA, Ralph DJ. BJU Int. 2009 Sep;104(6):852-6
3. Total Urethral Construction with the Radial Artery-based Forearm Free Flap in the Transsexual. Giulio Garaffa, David J Ralph, Nim Christopher. BJU Int 2010; 106 (8): 1206-10.
4. Total Phallic Reconstruction in Female-to-Male Transsexuals. Garaffa G, Christopher NA, Ralph DJ. Eur Urol. 2010 ;57(4):715-22
5. Overall satisfaction, sexual function, and the durability of neophallus dimensions following staged female to male genital gender confirming surgery: the Institute of Urology, London U.K. experience. Garcia MM, Christopher NA, De Luca F, Spilotros M, Ralph DJ. Transl Androl Urol. 2014 Jun;3(2):156-62.